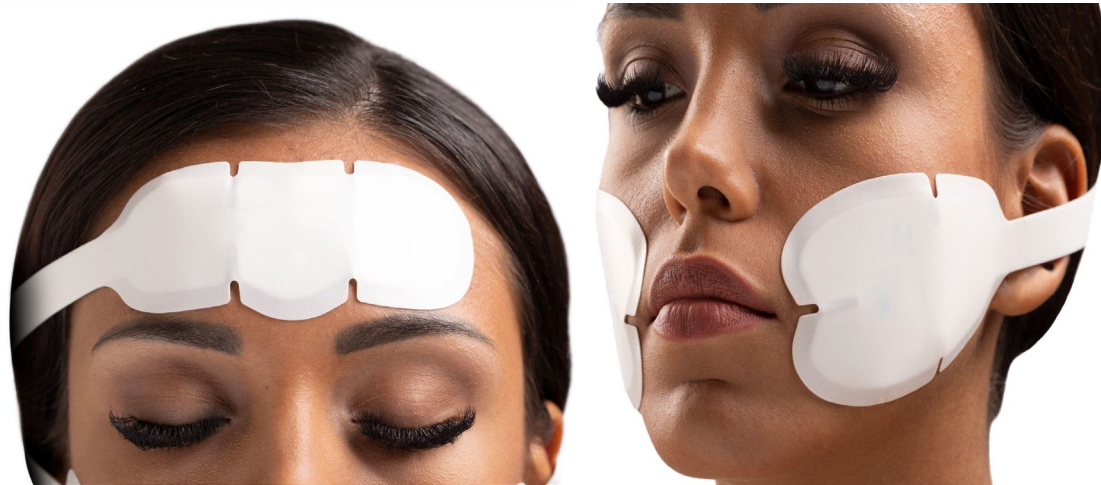



Yael Halaas, M.D., FACS
Yael Halaas, MD, New York, NY

Rebuilding Facial Muscle - Changing the Aging Paradigm

Yael Halaas, M.D., FACS
Yael Halaas, MD, New York, NY

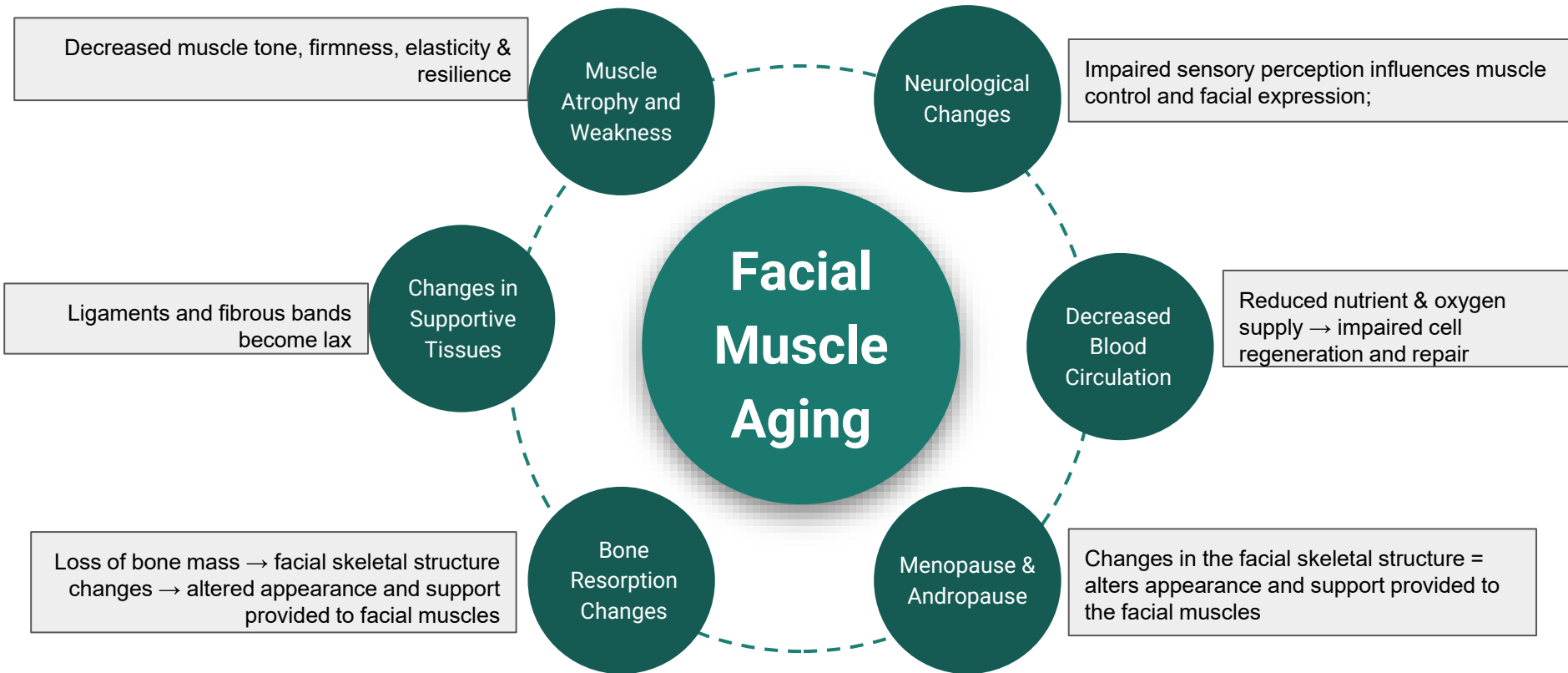


Background

- Anti-aging facial treatments have gained popularity over the past few decades.
- These treatments - non-surgical or surgical - **aim to rejuvenate the face by addressing the various changes that occur with aging.**
- Popular treatments that target facial muscles include **neurotoxin injections, which temporarily paralyzes targeted facial muscles to reduce the appearance of dynamic wrinkles.**
- On the more invasive side, **facelift surgeries often involve adjusting or tightening the facial layers (SMAS, muscles) in addition to removing excess skin/fat. {1 - 4}**

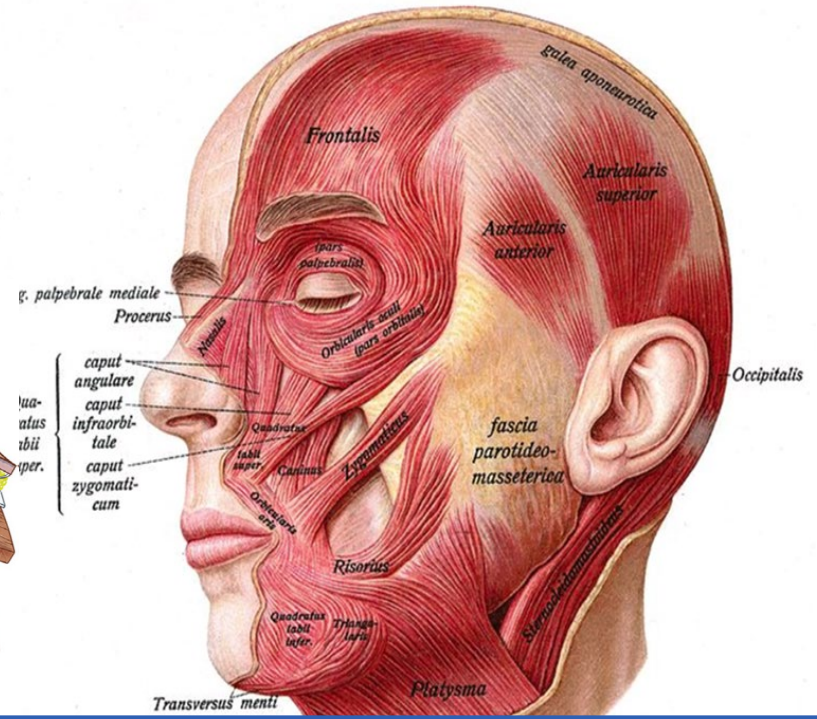
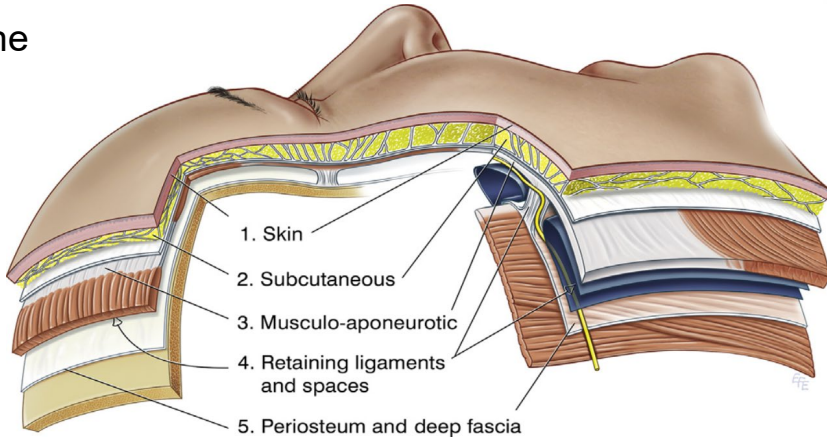


Understanding the Aging process



Important facial structures

- Skin
- Fat compartments
- Superficial musculoaponeurotic system (SMAS)
- Muscles
- Bone



Facial Muscle Functional Changes

FUNCTIONAL CHANGE

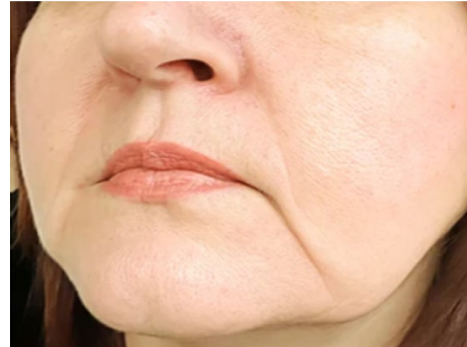Reduced mobility

Gravity

Formation of expression
& sleep lines

Facial asymmetry


Sagging and Laxity



Aims of facial muscle treatments/techniques

The main objectives of anti-aging facial muscle treatments are:

- **Reducing dynamic wrinkles and fine lines:** to soften frown lines, crow's feet, and forehead lines **by relaxing underlying muscles.**
- **Volume restoration:** to counter facial sagging and hollowing.
- **Lifting sagging structures: brows, cheeks, and neck.**
- **Enhancing contours: a pronounced jawline and high cheekbones.**
- **Balancing facial symmetry:** by addressing individual facial muscles or areas of concern, asymmetry may be corrected. {5-8}



Facial Muscle Anti-aging Interventions

The current industry standard

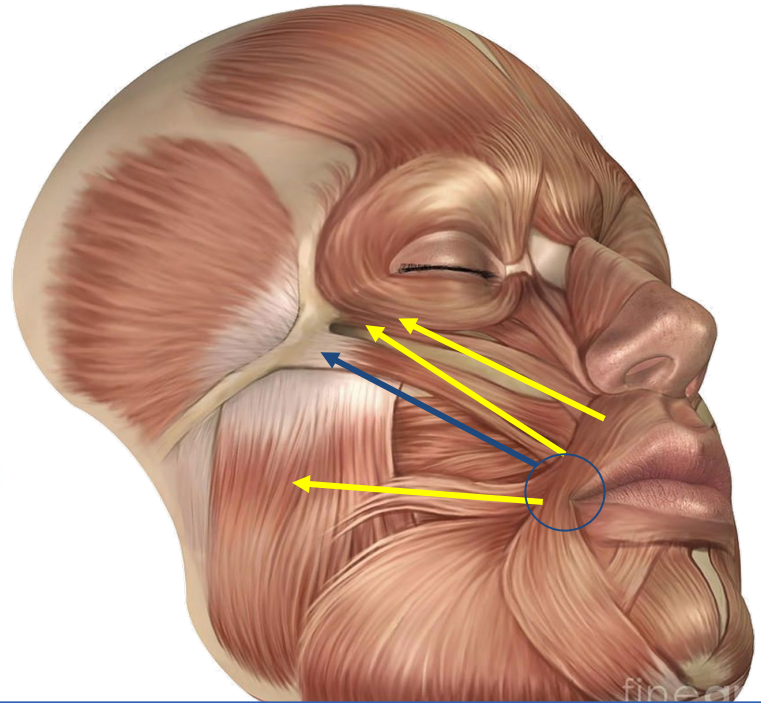
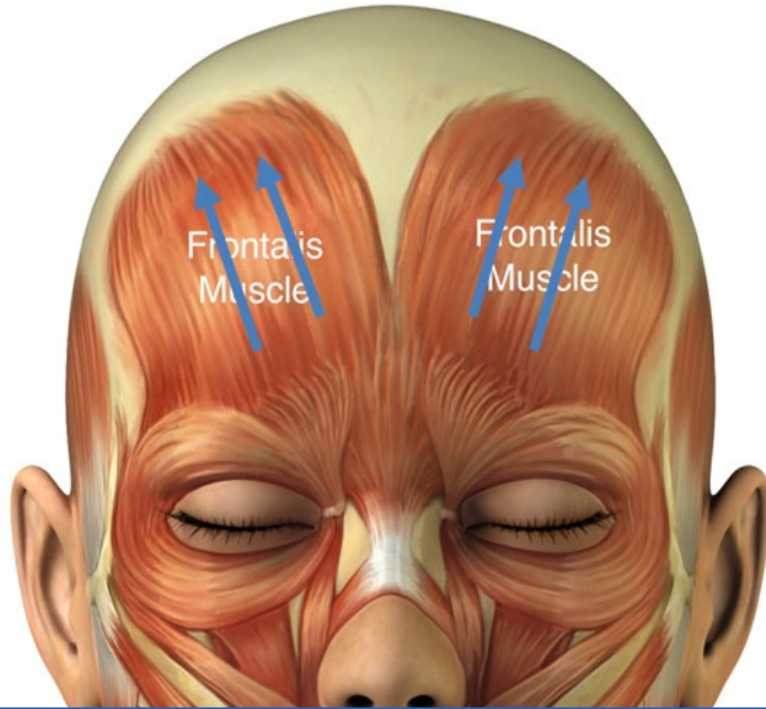
- **Botox injections** - botulinum toxin to relax facial muscles
- **Facelift** - repositioning SMAS to create a smoother, youthful facial contour
- **Neck lift** - tightening and enhancing the SMAS

New innovations on the horizon

1. Stem cells (autologous transplants; growth factors)
2. Collagen and myogenic peptides
3. Regenerative medicine (platelet-rich plasma; gene therapy; exosomes)
4. **skin surface treatments - High intensity electrical facial stimulation (HIFES) to tone facial muscles {9-14}**

Regenerative and Preventative medicine have become key interests in enhancing facial appearance to maintain a youthful look. Some treatments, when started earlier in life, can prevent/delay the onset of certain signs of aging by maintaining the health and tone of facial muscles;

Muscles of Interest



HIFES technology - Muscles of Interest

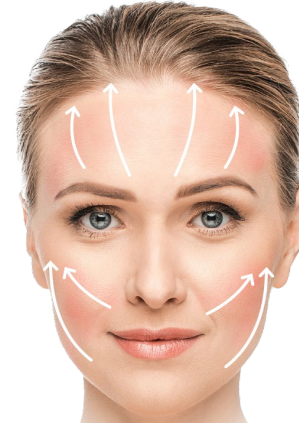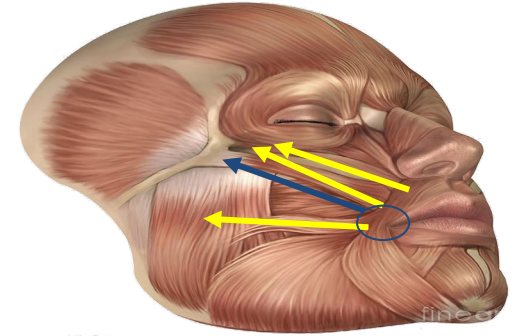
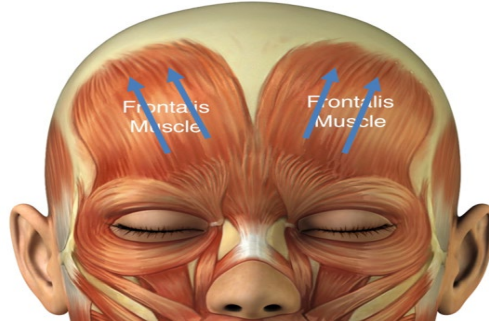
Improves facial contours by selectively contracting elevator facial muscles

Forehead & Eyebrows:

- **Frontalis**

Cheeks & Jawline:

- **Zygomaticus major**
- **Zygomaticus minor**
- **Risorius muscles**



Novel 2-IN-1 PROCEDURE

HIFES + SYNCHRONIZED RF

Reinforces facial muscle structure

Affects supportive tissue fascia which aid in maintaining soft tissue in position

Improves tissue laxity and skin texture

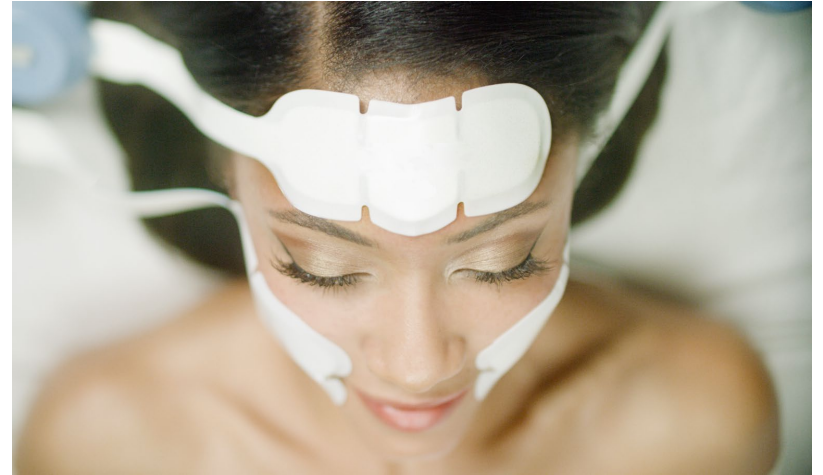

Muscle Quality Improvement Underlines the Non-invasive Facial Remodeling Induced by a Simultaneous Combination of a Novel Facial Muscle Stimulation Technology with Synchronized Radiofrequency

Yael Halaas, M.D., FACS
Yael Halaas, MD, New York, NY, USA

Study Objective

To determine the improvement in quality of facial muscles after RF+HIFES treatments via changes in echo intensity ultrasound evaluation



Muscle Quality Improvement Ultrasound Study

STUDY DESIGN

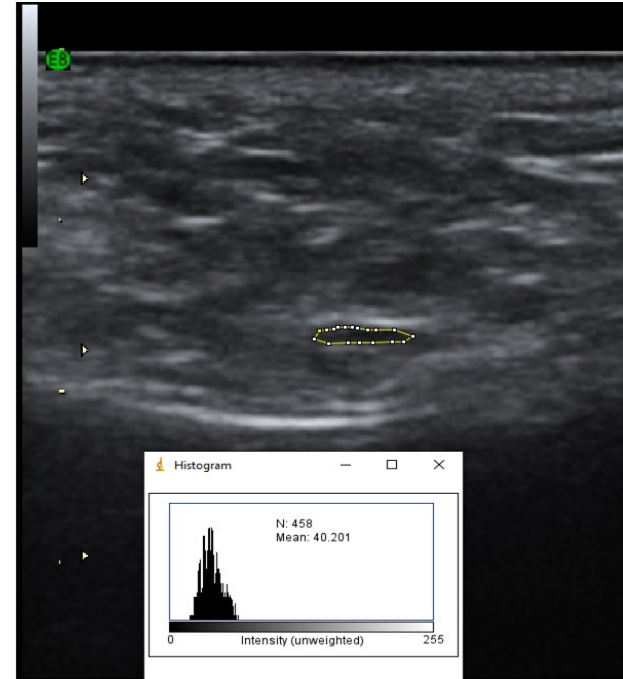- 10 patients enrolled (9 F, 1 M)
 - 59.7±1.9 years, skin types I-IV
 - All patients treated with HIFES+RF
 - Four 20-minute treatments (one treatment 5-10 days apart)
 - forehead and both cheeks treated simultaneously
 - Parameters set to maximum tolerable level

EVALUATION METHODS

- Ultrasound scans of m. frontalis and m. zygomaticus major taken at baseline, 1-month and 3-month follow-up
- Muscle echogenicity (also known as Echo Intensity - EI) was determined
- Satisfaction & Comfort evaluated via questionnaires
- Facial aesthetic improvement evaluated (GAIS)

Echo Intensity of facial muscles

- Muscle quality of targeted area assessed by measuring the **cho intensity (EI)**
- EI represents the **mean pixel intensity** of a specific region from an ultrasound image
- Increased EI (brighter color) = high amount of intersected connective tissue in muscle thus cause decrease in muscle quality
- **Decreased EI** (darker color) = **increase in muscle quality**



Exemplary ultrasound scan analysis, m. zygomaticus major (Including histogram of pixel intensity)

Results - Photographs

Muscle Quality Improvement Ultrasound Study

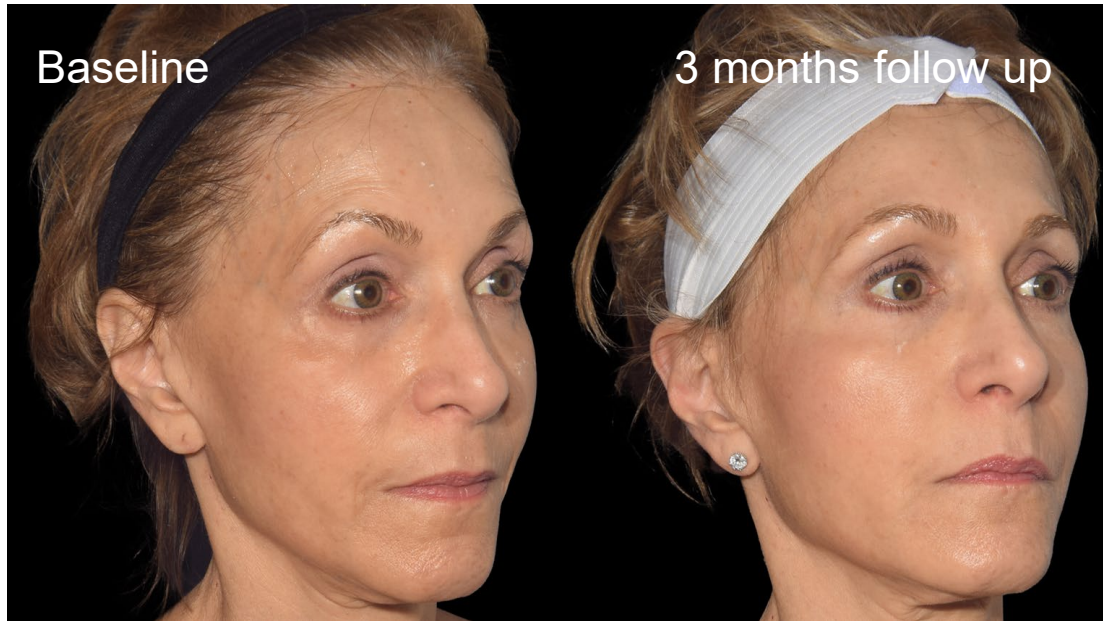

Figure 1: 66-year-old female. Comparing baseline (left) to 3 months (right), the skin appears to be lifted - notably in the nasolabial fold region and forehead area and cheek volume increase.

Results

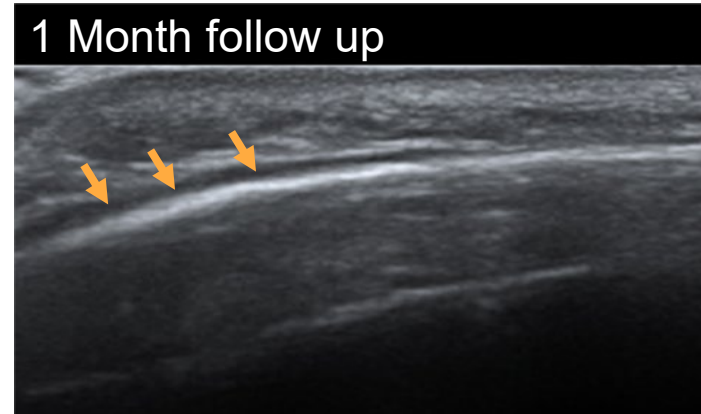
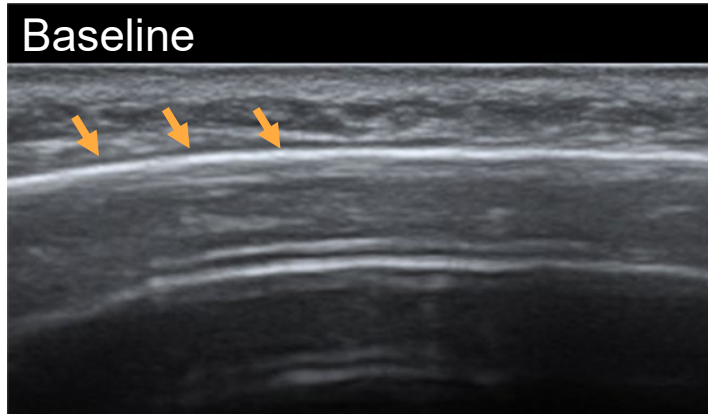
Muscle Quality Improvement Ultrasound Study

Aesthetic Improvement

- 87.5% had at least 1 grade improvement of GAIS score 3 months post-treatment.
- 93% satisfied with outcome & rated treatment as comfortable

Echo Intensity

- decreased in both zygomaticus major (ZM) and frontalis (FM) muscles at 3 months follow up
- mean EI values at 3 months compared to baseline:
 - FM: 19.9 A.U. (-19.9%, $p < 0.001$)
 - ZM: 24.9 A.U. (-30.00%, < 0.001)



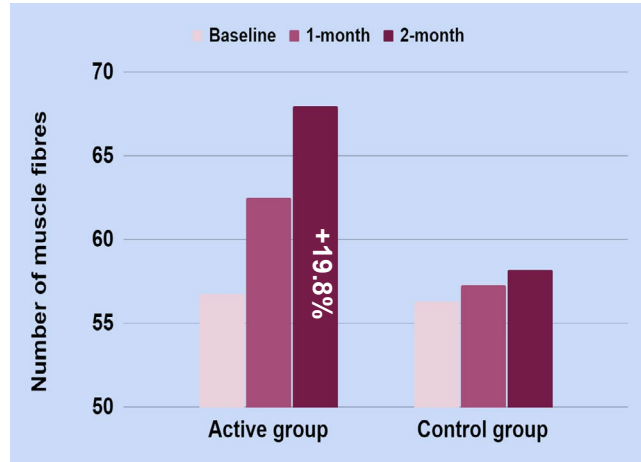
HIFES+RF Study on Muscle Tissue: Porcine Histology Study

Brian M. Kinney, M.D., FACS¹, MVDr. Jan Bernardy Ph.D.², Rea Jarosova MSc²

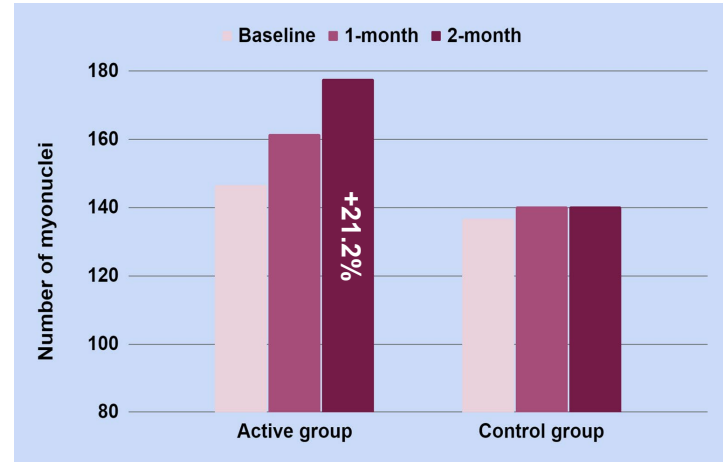
1. Division of Plastic Surgery, The University of Southern California Keck School of Medicine, Beverly Hills, CA, USA School of Medicine, Los Angeles, CA, USA

2. Veterinary Research Institute, Brno, CZ

Objective: to determine the effects of novel HIFES technology combined with RF for the strengthening of delicate facial muscles on a porcine model.



- Active group: **+19.8% muscle fiber count**
- Control group: no significant change ($p>0.05$)



- Active group: **+21.2% myonuclei count** ($p<0.05$)
- Control group: no significant changes ($p>0.05$)

HIFES+RF Study on Muscle Tissue: Porcine Histology Study

Images courtesy of Brian M. Kinney, M.D., FACS

Muscle temperature evaluation during treatment:
muscle tissue temperature reached 39.5°C within the initial 2-3 minutes and remained fundamentally stable for the remaining duration.

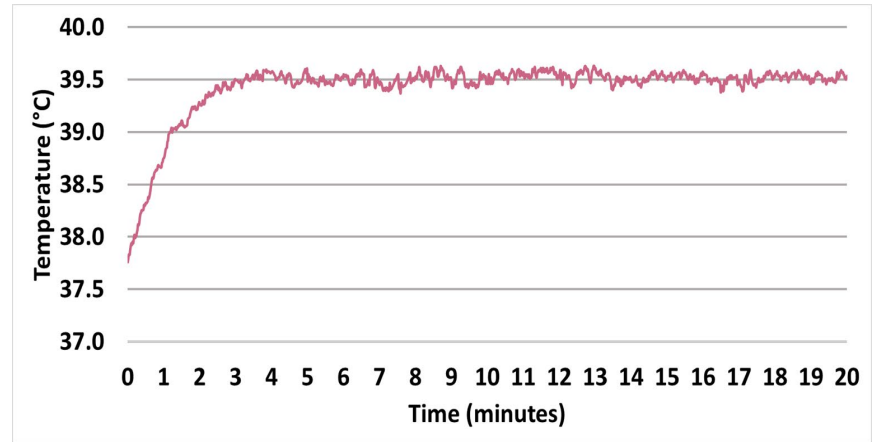
2-months follow up results:

1. **Muscle Density:** +19.2% increase ($p < 0.001$)
2. **Number of Muscle Fibers:** +19.8% increase ($p < 0.001$)
3. **Number of Myonuclei:** +21.2% increase ($p < 0.05$)

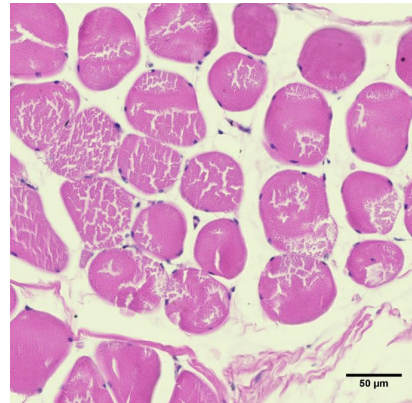
Observable

- Decrease of fat and fibrotic tissue
- Improved muscle structure

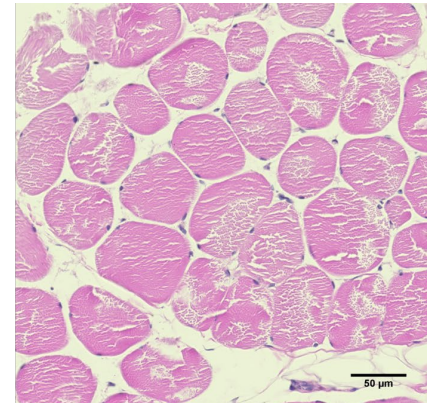
Kinney BM, Bernardy J, Jarošová R. Novel Technology for Facial Muscle Stimulation Combined With Synchronized Radiofrequency Induces Structural Changes in Muscles Tissue: Porcine Histology Study. Aesthetic Surgery Journal. Published online March 8, 2023:sjad053. doi:10.1093/asj/sjad053



Baseline



2 Months



Conclusion

HIFES and synchronized RF present a new approach in Facial Aesthetics

The treatment, delivered through non-invasive, handsfree, self-adhesive applicators:

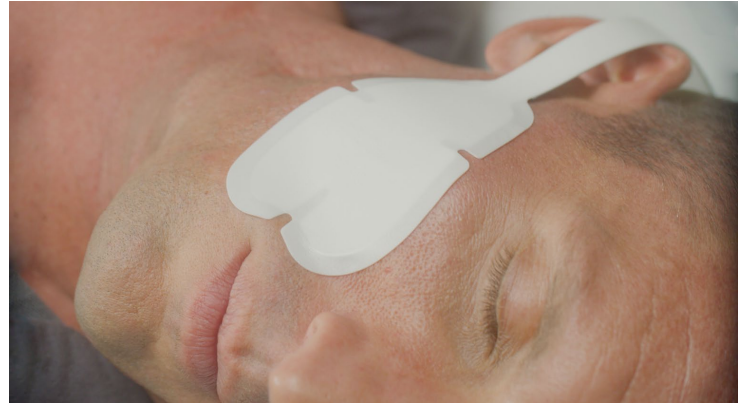- Stimulates connective tissue fascia and muscle
- Induces contractions in the facial elevator muscles
- Improves muscle tone
- Results in lifting effect on forehead and cheeks
- Building the supportive structure for the facial soft tissues

30%

INCREASE IN
MUSCLE TONE

19%

MUSCLE
DENSITY



SOURCES AND REFERENCES

Literature

1. Cotofana S, Fratila AA, Schenck TL, Redka-Swoboda W, Zilinsky I, Pavicic T. The Anatomy of the Aging Face: A Review. *Facial Plast Surg*. 2016 Jun;32(3):253-60. doi: 10.1055/s-0036-1582234. Epub 2016 Jun 1. PMID: 27248022.
2. Swift A, Liew S, Weinkle S, Garcia JK, Silberberg MB. The Facial Aging Process From the "Inside Out". *Aesthet Surg J*. 2021 Sep 14;41(10):1107-1119. doi: 10.1093/asj/sjaa339. PMID: 33325497; PMCID: PMC8438644.
3. Le Louarn C. Vieillesse musculaire et son implication dans le vieillissement facial : le concept du Face Recurve®. *Annales de Dermatologie et de Vénéréologie*. 2009;136:S67-S72. doi:10.1016/S0151-9638(09)74530-2
4. Cotofana S, Assemi-Kabir S, Mardini S, Giunta RE, Gotkin RH, Moellhoff N, Avelar LET, Mercado-Perez A, Lorenc ZP, Frank K. Understanding Facial Muscle Aging: A Surface Electromyography Study. *Aesthet Surg J*. 2021 Aug 13;41(9):NP1208-NP1217. doi: 10.1093/asj/sjab202. PMID: 33942051
5. Beylot C. Vieillesse cutanée – Vieillesse faciale globale : orientation thérapeutique [Skin ageing-General features of facial ageing and therapeutic choices]. *Ann Dermatol Venerol*. 2019 Jan;146(1):41-74. French. doi: 10.1016/j.annder.2018.10.015. Epub 2018 Dec 20. PMID: 30581032.
6. Coimbra, D.D., de Oliveira, B.S., Uribe, N.C. (2016). Evaluation and Classification of Aging. In: Issa, M., Tamura, B. (eds) *Daily Routine in Cosmetic Dermatology. Clinical Approaches and Procedures in Cosmetic Dermatology*. Springer, Cham. https://doi.org/10.1007/978-3-319-20250-1_4-1
7. Lem, M., Pham, J.T., Kim, J.K. et al. Changing Aesthetic Surgery Interest in Men: An 18-Year Analysis. *Aesth Plast Surg* (2023). <https://doi.org/10.1007/s00266-023-03344-9>
8. Montes JR, Santos E. Evaluation of Men's Trends and Experiences in Aesthetic Treatment. *J Drugs Dermatol*. 2018 Sep 1;17(9):941-946. PMID: 30235379.
9. Ilankovan V. Anatomy of ageing face. *Br J Oral Maxillofac Surg* (2013), <http://dx.doi.org/10.1016/j.bjoms.2013.11.013>
10. Khan HA, Bagheri S. Surgical anatomy of the superficial musculo-aponeurotic system (SMAS). *Atlas Oral Maxillofac Surg Clin North Am*. 2014 Mar;22(1):9-15. doi: 10.1016/j.xcom.2013.11.005. PMID: 24581561.
11. Stark, S., Stark, C., Wong, B. et al. Modulation of amygdala activity for emotional faces due to botulinum toxin type A injections that prevent frowning. *Sci Rep* 13, 3333 (2023). <https://doi.org/10.1038/s41598-023-29280-x>
12. Xu X, Zhang H, Yan Y, Wang J, Guo L. Effects of electrical stimulation on skin surface. *Acta Mech Sin*. 2021;37(12):1843-1871. doi: 10.1007/s10409-020-01026-2. Epub 2021 Feb 6. PMID: 33584001; PMCID: PMC7866966.
13. Lim HW. Effects of Facial Exercise for Facial Muscle Strengthening and Rejuvenation: Systematic Review. *J Kor Phys Ther*. 2021;33(6):297-303. doi:10.18857/jkpt.2021.33.6.297
14. Kavanagh S, Newell J, Hennessy M, Sadick N. Use of a neuromuscular electrical stimulation device for facial muscle toning: a randomized, controlled trial. *J Cosmet Dermatol*. 2012 Dec;11(4):261-6. doi: 10.1111/jocd.12007. PMID: 23174048.
15. Consulin MCD, Vasques LI, Leonardi GR. Neuromuscular Electrical Stimulation in Facial Aging: an Integrative Literature Review. *Fisioter Pesqui*. 2023;30:e21008423en. doi:10.1590/1809-2950/e21008423en

Outsourced images

- <https://aestheticsjournal.com/feature/case-study-male-facial-rejuvenation>
- <https://www.shutterstock.com/image-photo/portrait-showing-flabbiness-adipose-sagging-skin-2187944269>
- <https://www.shutterstock.com/image-photo/woman-face-wrinkles-after-treatment-1674169819>
- <https://www.dreamstime.com/stock-photo-elderly-woman-pulling-skin-her-jowls-cheeks-pinching-fingers-showing-ageing-process-beauty-image70516881>
- https://commons.wikimedia.org/wiki/File:Sobo_1909_260.png
- https://www.researchgate.net/publication/353288087_The_Path_to_an_Evidence-Based_Treatment_Protocol_for_Extraoral_Photobiomodulation_Therapy_for_the_Prevention_of_Oral_Mucositis
- <https://www.gettyimages.no/photos/tanaka-face>
- <https://www.starecta.com/asymmetry-of-the-eyes-in-photos/>
- <https://fineartamerica.com/featured/anatomy-of-human-face-muscles-stocktrek-images.html?product=canvas-print>
- <https://www.centerforfacialappearances.com/2019/04/01/3636/>
- <https://www.gettyimages.es/detail/foto/woman-with-facial-muscle-structure-painted-on-imagen-libre-de-derechos/103937616?adppopup=true>
- <https://www.health.harvard.edu/staying-healthy/why-your-face-ages-and-what-you-can-do>

Thanks for Your Attention!



@DRHALAAS

YH
SCIENCE & BEAUTY